

AKTUÁLNÍ ČÍSLO

ARCHÍV

PERIODIKUM

VYHLEDÁVÁNÍ

REDAKČNÍ RADA

Aktualizované

POKYNY PRO AUTORY

INSTRUCTIONS
TO AUTHORS

PŘEDPLATNÉ

SUBSCRIPTION

INZERCE



Zdravotnické
nakladatelství
Galén



© Česká společnost
pro ortopedii
a traumatologii 2006

Úvodní strana / Home

Webmaster

Provozovatel webu

Souborný referát / Current concepts review

ACTA CHIRURGIAE ORTHOPAEDICAE ET TRAUMATOLOGIAE ČECHOSL.,
79, 2012, p. 97 - 106

Zlomeniny talu. Současný pohled z hlediska diagnostiky, léčby a výsledků

Talus Fractures: A Current Concepts Review of Diagnoses, Treatments, and Outcomes

J. M. LAMOTHE, R. E. BUCKLEY

University of Calgary, Health Sciences Centre, 3300 Hospital Drive, NW, Calgary, AB, Canada

SUMMARY

The talus is the key articular segment linking the leg and foot, and as such, is subject to complex loads and may occasionally fracture. Fracture patterns provide clues to the underlying pathomechanics and energy of the injury, both of which can help guide treatment and suggest prognosis. Talus fractures have a wide variety of presentation from low-energy avulsion fractures of the lateral or posterior processes, to high-energy comminuted talar body fractures. Appropriate, expedient treatment provides the patient the best chance of obtaining a good functional outcome. Treatment relies on appropriate diagnosis, which hinges on clinical suspicion provided by the patient's account of pathomechanics, clinical examination, and radiological workup. This current concepts review discusses the pathomechanics, presentation, workup, treatment, and prognosis of fractures of the talar head, neck, body, lateral process, posterior process, and talar extrusions.

Key words: talus, fracture, talar neck, talar head, talar body, lateral process, posterior process, talar extrusion, orthopaedic surgery, review

INTRODUCTION

The talus is the crucial intercalary articular segment connecting the leg to the foot, and is unique in that it is the only tarsal bone lacking muscular or tendinous attachments. The ability of the foot to function simultaneously as a supple shock absorber and rigid lever arm relies on the complex geometry of the talus, and pattern of motion through the transverse tarsal and subtalar joints (26). As such, talar injuries may be catastrophic. Open talus fractures were associated with high-energy mechanisms and had a reported mortality rate of 84% in 1848 (52, 63). Early 19th and 20th century literature on talus fractures was dominated by case reports until the large case series (18 patients) by Anderson in 1919 (2). Anderson was a Consulting Surgeon to the Royal Flying Corps in World War I and noted the association of talus fractures with aviation. Anderson postulated that injuries occurred because the pilot's feet were on the rudder bar when planes crashed into the ground, which concentrated force on the astragalus resulting in fracture; thus the term 'Aviators Astragalus' (2). His World War I data was supported by World War II data from Coltart, an orthopaedist and Wing Commander for the Royal Air Force (14). During 1940-1945, 25,000 fractures and dislocations were treated and there were 228 talus injuries (-1%). Of these, 70% of the serious talus injuries were caused by aviation, justifying the original title 'Aviators Astragalus' (2, 14). With the current advent of safety equipment that allows patients to survive previously fatal injuries (e.g. airbags and seatbelts), talus fractures are becoming more common to orthopaedic surgeons (1, 21). Modern understanding of talus anatomy and vascularity has helped elucidate fracture patterns, clarify long-term complications, and plan treatment protocols.

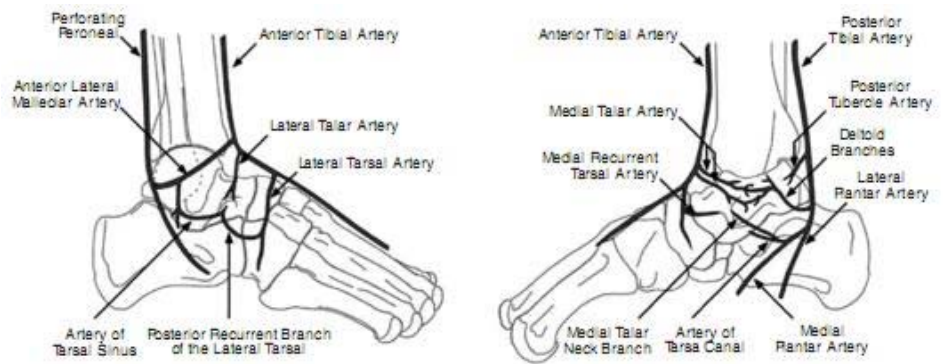


Fig. 1. Vascular supply of the talus.

Anatomy

Approximately 60% of the surface of the talus is covered with articular cartilage by way of articulations with the tibia, fibula, calcaneus, and navicular. As such, talus fractures are frequently intraarticular. Superiorly, the saddle shaped articulation of the talar body is wider anteriorly, and is congruent with the distal tibia. The talar body has a medial articular facet that articulates with the medial malleolus and distally is collinear with the talar neck. The lateral articular surface of the body flares laterally and becomes the lateral process of the talus, which articulates with the fibula superiorly and the posterior facet of the calcaneus inferiorly. The posterior portion of the talar body flares posteriorly and creates a posterior process, which composes a portion of the posterior facet of the concave subtalar joint articulation. The posterior process is divided into medial and lateral tubercles. The valley between the two tubercles houses the flexor hallucis longus tendon. There are two other subtalar facets; anterior and medial facets. Distal to the talar body lies the neck of the talus, which is devoid of articular cartilage and angled approximately 25° medial and inferior to the axis talar body. The talar neck connects the talar body to the talar head, which forms the "acetabulum pedis" with the navicular. In general, fractures of the talus can be divided into talar neck, talar head, talar body, and processes/avulsion fractures.

Vascularity

Given the lack of musculotendinous attachments on the talus, the talus derives its blood supply from a vascular sling around its neck and perforating branches (Fig. 1). The vascular orientation and subsequent retrograde flow to the talar body has been blamed for the traditionally high rate of avascular necrosis (AVN) of the talar body with displaced talar neck fractures (24, 27). More recent reports have shown a smaller risk of AVN than was traditionally published (22, 67), which may be due to a strong posterior blood supply of the talus with a rich intraosseous anastamotic framework (30). The talus receives its blood supply from three main arteries which form an anastamotic sling around the talar neck; the peroneal artery, the anterior tibial artery, and the posterior tibial artery (24). The talus is lacking cartilage at the talar neck, medial talar body inferior to the medial malleolus, the sinus tarsi, and the posterior tubercle; these sites are critical points of entry for talus vasculature (51). In a recent cadaveric gadolinium-enhanced MRI study, Miller et al. (2011) found that the posterior tibial artery supplied 47% of the entire vascularity of the talus, the anterior tibial artery supplied 36.2%, and the peroneal artery supplied 16.9% (30). Furthermore, the posterior tibial artery dominated the blood supply to the talus in all quadrants of the talus, except for the anteromedial quadrant of the talus where the majority of the blood supply came from the anterior tibial artery (30). There was a predictable dense anastamotic network of vessels from the peroneal and posterior tibial arteries around the posterior tubercle of the talus, as well as between the arteries of the tarsal canal and sinus tarsi within the tarsal canal and talus (30). The traditionally described deltoid branch of the posterior tibial artery was highly variable in size and location. The posterior tibial artery has two entry points; one in the tarsal canal and one at the posterior tubercle, which provides some anterograde blood supply to the talar body (30, 51).

TALAR NECK FRACTURES

Pathomechanics

Given the unique shape and location of the talus, a significant load is often required to fracture the talar neck. The exact mechanism may be from either a hyperdorsiflexion force (48), or from an axial load to the forefoot while the talus is fixed between the calcaneus and tibia (50). Many patients with talar neck fractures are poly-traumatized (67) and as such, it is important to sufficiently assess the patient in accordance with Advanced Trauma Life Support (ATLS) protocols and rule out associated injuries. Because of the high degree of energy required to fracture the neck of a talus, most talus fractures are displaced, and if not anatomically reduced can be associated with severe complications such as hindfoot deformity, arthritis, or AVN. The radiographic workup (x-ray) to characterize talar neck fractures is an ankle series (anteroposterior (AP), lateral, and mortise) and foot series (AP, lateral, and oblique). The Canale view may also assist in viewing the talar neck (place the foot in maximal equinus on the x-ray cassette, pronate the foot 15°, and direct the x-ray beam 75° cephalad from the horizontal). Given the complex pattern of the fracture with possibility of osteochondral fragments, computed tomography (CT) should be routinely used to help with preoperative planning.

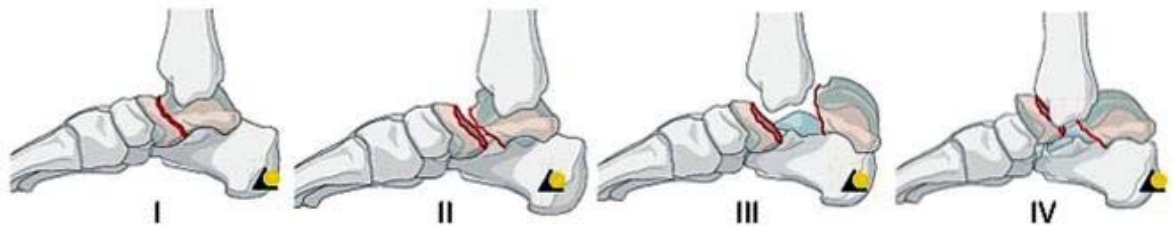

Fig. 2. Hawkins talar neck classification; types I-IV.

Classification

Hawkins classified talar neck fractures by displacement, and there is a recognized increased risk of AVN with increasing displacement of the fracture (12, 27). Type I is a nondisplaced talar neck fracture, and Types II, III, IV are all displaced (Fig. 2). Type II is characterized by a subluxation or dislocation of the subtalar joint, Type III is a type II with subluxation or dislocation of the tibiotalar joint, and Type IV is a type III with talonavicular joint subluxation or dislocation. Special attention should be paid to the presence of medial neck comminution because it may alter the surgical treatment.

Indications for surgery/Nonoperative management

Patients with displaced talar neck fractures should be treated operatively due to a high risk of nonunion, malunion, altered foot mechanics, subtalar arthritis, and AVN with nonoperative management. The role for nonoperative management in talar neck fractures is limited to patients who have nondisplaced fractures (confirmed via CT), or in patients who are unable to have surgery for medical reasons. Patients treated nonoperatively should be followed frequently and closely for displacement, and will be non-weight bearing in a well-molded cast for 8 weeks, followed by mobilization in a cast for 6 weeks.

Operative management

Initial fracture management includes a closed reduction on presentation (in the presence of severe subluxations or dislocations), which can be achieved by flexing the knee and plantarflexing the foot to bring the talar head to the position of the talar body. Adequate conscious sedation is often required. In the event of an irreducible talar neck fracture, and open reduction with internal fixation should be performed as soon as possible to prevent progressive soft tissue compromise.

Timing of open reduction and internal fixation

Irreducible fracture dislocations require an emergent closed and possible open reduction. Once a reduction is obtained, most orthopaedists do not believe that an emergent operation is needed for displaced talar neck fractures (46). Several studies that show there is no apparent increase in complications with increasing time from injury to operative fixation (7, 35, 55, 67). Definitive management should be conducted as soon as an experienced surgical team can safely perform the surgery, with special attention paid to the soft tissues quality. If there is significant swelling, the surgery can be staged until the quality of the soft tissue permits a safe surgical dissection with primary incision closure.

Approach

Obtaining an anatomic reduction of talar neck fractures is critical because a small amount of varus neck malalignment may substantially limit subtalar eversion and increase subtalar joint contact stresses (15,56). Talar neck fractures often have a tensile failure laterally, and compressive failure medially. Accordingly, the lateral fracture pattern may often be simple, and the medial neck fracture may have comminution. Direct visualization of the talar neck on the medial and lateral sides is often required to facilitate an anatomic reduction. The authors advocate for a combined anteromedial and anterolateral approach. In cases where the neck fracture is proximal, or if there is a body fracture associated with the talar neck fracture, a medial malleolar osteotomy can be used to enhance fracture visualization.

Fixation

Once reduction of the talar neck fracture is obtained, there are many options available for fixation including Kirschner-wires (K-wires), anterior to posterior screws, posterior to anterior screws, and plates (6). Both anterior to posterior and posterior to anterior screws are stronger than K-wires (62). The authors do not recommend the routine use of K-wires for talar neck fixation, because they may not adequately hold the reduction to permit early range of motion. Regardless of what fixation is chosen, areas of comminution (usually dorsomedially) should be held out to length with a fully threaded screw(s) or a plate/screw construct, and areas of anatomic reduction should be compressed with lag screws. The benefit of posterior to anterior directed screws is that the fixation typically crosses the fracture perpendicularly, which may increase the strength of the fixation (62). However, a recent biomechanical study by Attiah et al (2006) found that there was no difference in fixation strength to yield point between anterior to posterior screws, posterior to anterior screws, and a medial sided plate with a lateral screw (6). All of their fixation constructs were able to withstand greater than 1.1 kN, which is the calculated shear force across the talar neck during active range of motion (62). The potential drawbacks of posterior to anterior directed screws are the technical challenges of intra-operative positioning, the risk of damage to articular cartilage, and damage to

neurovascular structures (18). This is particularly important given the recent vascular study by Miller et al. (2011) that found a major anterograde vessel supplying the talar body and entering the posterior tubercle (30, 51).

Outcomes

Talar neck fractures are potentially disabling high energy injuries⁵⁵. Outcomes of patients with displaced talar neck fractures are dependent upon the development of early and late complications, which may lead to secondary reconstructive surgeries (55). In a retrospective cohort study by Sanders et al (2004), 70 patients with displaced talar neck fractures were assessed (55). Patients without varus malalignment or radiographic arthrosis had excellent functional outcomes. However, patients with varus hindfoot alignment, subtalar joint space loss, and comminuted fractures did significantly worse and often required secondary reconstructive surgeries (55). Based upon life table analyses, they found that the percentage of patients requiring secondary surgery was 48% at 10 years. Possible immediate and long term complications after talar neck fractures include wound infection, wound dehiscence, deep infection, delayed union, nonunion, malunion, AVN and talar dome collapse, ankle osteo-arthritis, subtalar arthritis, and pantalar arthritis (35, 55, 67). The most common complication requiring secondary surgery is subtalar arthritis with reported rates of up to 100% on long term follow up (35, 55). Patients with talar neck fractures should be counselled that they have a high risk of developing subtalar arthritis, which may require secondary reconstructive procedures such as subtalar or pantalar fusions.

The risk of developing talar dome AVN is highly variable with rates increasing with increasing Hawkins grading (27, 67). In his original paper, Hawkins published no AVN in type I, 42% AVN with type II, and 91% AVN with type III. More current literature suggests the rate may be lower than was originally published (22,44, 55,64,67). In a retrospective series of 102 patients, Valuer et al. (2004) found AVN in 39% of type II fractures, and 64% of type III fractures (67). In another large retrospective series, Sanders et al. (2004) found the overall rate of AVN to be 11% for 70 patients with displaced talar neck fractures (29 type II, 25 type III, 16 type IV), with no apparent predilection for higher rates of AVN with a higher Hawkins grading⁵⁵. Talar dome vascularity post-fracture can be identified by a positive Hawkins sign (relative subchondral osteopenia in the talar dome post-injury) (65). Hawkins sign appears between the 6th and 9th week post trauma, and has a sensitivity of 100% and specificity of 57.7%, meaning that if a patient develops a Hawkins sign, they are highly unlikely to go on to late AVN (65). If AVN develops, normal talar dome density can return in many cases, even in the presence of normal weight bearing without bracing (67). Furthermore, AVN is not always associated with dome collapse. Two risk factors for dome collapse with AVN are neck comminution and open injuries (67). If dome collapse develops, patients should be managed symptomatically. Many salvage surgeries can be performed later including Blair fusions, pantalar fusions, or talectomies (55) (Fig. 3 and Fig. 4).

TALAR BODY FRACTURES

Definition

Talar body fractures range from talar dome osteo-chondral injuries to comminuted body fractures with tibiotalar and subtalar joint involvement. Given the wide disparity of mechanism, treatment, and prognosis of these injuries, the AO classification system has created three separate classifications for talar body fractures; C1 (osteochondral injury to the superior dome of the body), C2 (coronal split in the talar body demonstrating both tibiotalar and subtalar joint involvement), and C3 (comminuted talar body). For the purposes of this paper, talar body fractures will refer to C2 and C3 fractures, and C1 injuries will be considered talar osteochondral injuries and will not be discussed. Distinguishing between talar body and talar neck fractures can be difficult given the natural confluence between the neck and body. As such, Inokuchi et al. (1996) created a classification system based on the inferior fracture line and its location with respect to the lateral process of the talus (29). If the fracture line exits anterior to the lateral process, it is a talar neck fracture and if it extends into the lateral process it is termed a talar body fracture (29). By definition, talar body fractures are intraarticular fractures that involve the tibiotalar and subtalar joints, whereas talar neck fractures are extraarticular or involve the medial facet of the subtalar joint only.

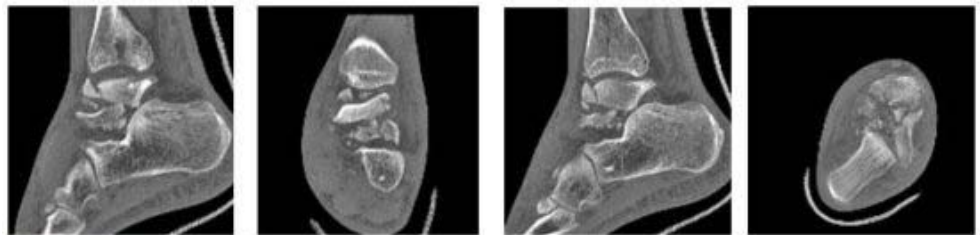


Fig. 3. Comminuted talus fracture, preoperative CT.

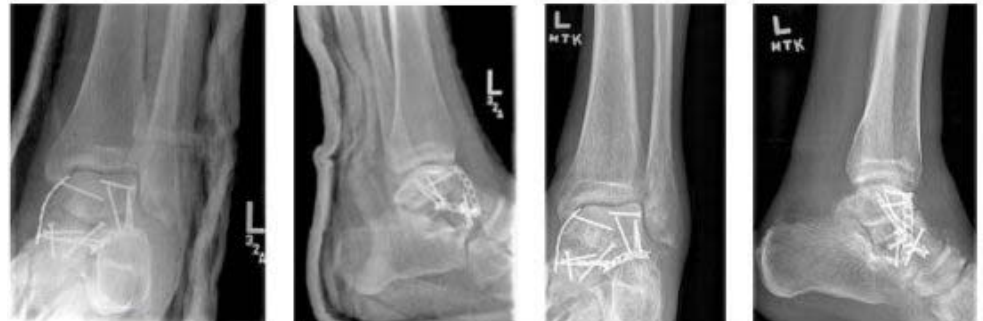

Fig. 4. Comminuted talus fracture, 6 and 26 weeks postoperative.

Pathomechanics/Treatment

Talar body fractures are rare, catastrophic injuries. Although there have been reports of talar body stress fractures in elite gymnasts (54), talar body fractures are much more commonly caused by large axial loads acting on the talus while it is fixed in position between the calcaneus and distal tibia. Talar body fractures represent approximately 25% of all talus fractures, are commonly caused by falls from height and motor vehicle collisions, and are frequently associated with talar neck fractures (68). The overall initial treatment of talar body fractures is similar to talar neck fractures; these patients are often polytraumatized and should be assessed in accordance with ATLS protocols. Following this, soft tissues should be assessed and joint dislocations should be reduced. Definitive management should be performed when patient medical condition and soft tissues permit. Standard anteromedial and anterolateral approaches can be used, and posterior talar body fractures often necessitate medial malleolar or fibular osteotomies to help with fracture visualization and instrumentation. Fractures should be treated with anatomic open reduction and internal fixation whenever possible. Nondisplaced fractures (CT proven) can be managed nonoperatively with a well-molded cast nonweightbearing; close radiographic follow-up to assess for fracture displacement is needed.

Outcomes

Early outcomes data for talar body fractures managed nonoperatively were abysmal, with up to 95% of patients having moderate to severe complaints (60). Sneppen et al. (1977) used this data to advocate for "exact reduction and stable fixation whenever possible" (60). Talar body fractures can be associated with the highest incidence of arthritis and worse outcomes in the tibiotalar and subtalar joints when compared with the talar neck and lateral and posterior process fractures (20). In the largest published series to talar body fractures treated with open reduction and internal fixation, Vallier (2003) reported a 38% prevalence of AVN, and half of these went on to collapse (68). Patients with AVN and collapse did worse than those without collapse. Open fractures and concurrent talar neck fractures were associated with AVN and collapse (68). Tibiotalar and subtalar arthritis were reported in 65% and 35% of patients, respectively (68). Late salvage procedures are determined by the pathology and include tibiotalar fusion, subtalar fusion, B lair fusion, talectomy, and amputation.

TALAR HEAD FRACTURES

Pathomechanics

Talar head fractures are much less common than talar neck and body fractures and as such, the published literature is characterized by occasional case reports. Talar head fractures may occur in isolation from a direct blow or axial load along the first ray, or may be an indicator of a greater injury. Talar head fractures are often difficult to characterize on plain x-rays, and accordingly CT scanning should be used to characterize the nature of the articular fracture.

Associated injuries/Treatment

The examiner must rule out other injuries to the foot and ankle if a talar head fracture is seen. Talar head fractures may be subtle a sign that a subtalar (33) or talo-navicular joint dislocation has occurred (53). The talo-navicular joint (also known as the acetabulum pedis) is the key joint to motion of the hindfoot (5) and thus, anatomic reduction is desirable. After ruling out associated injuries, displaced talar head fractures should be fixed anatomicallly with open reduction and internal fixation when possible. A dorsomedial approach over the talar head can be used, and fragments can be fixed with mini-fragment fixation where

possible. Areas of comminution can be spanned with a bridge plate or external fixator to help maintain length in the medial column of the foot. Avascular necrosis and nonunion are rare following talar head fractures.

Given how difficult these injuries can be to diagnose without a high clinical suspicion and appropriate cross sectional imaging, talar head fractures may present late. If the patient is presenting late without signs of radio-graphic arthroses, osteotomies can be used to correct the deformity (37). If there are painful clinical and radiographic signs of osteoarthritis, a talonavicular fusion or triple arthrodesis can be performed.

LATERAL PROCESS OF THE TALUS FRACTURES

Pathomechanics/Assessment

The lateral process of the talus is a unique structure with dorsolateral and inferomedial articular facets that articulate with the fibula and calcaneus, respectively. The lateral prominence is the site of insertion of the talocalcaneal ligament, and as such, it may be injured in an avulsive tensile fashion, or from large direct mechanical loads from the fibula or calcaneus. These injuries have

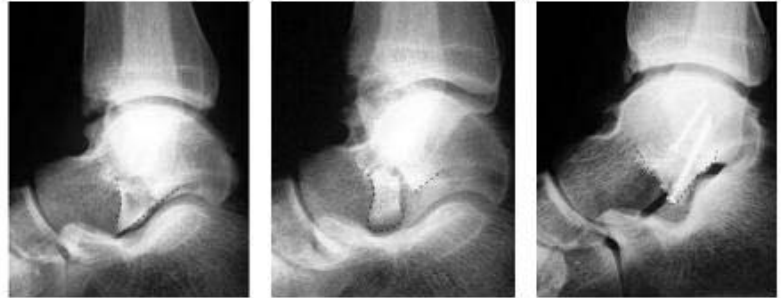

Fig. 5. "V-Sign" indicating a displaced lateral process of the talus fracture.

a high correlation with snowboarding, and as such, have been termed snowboarder's fractures (31, 38, 42). In the largest review of snowboarding foot and ankle injuries, Kirkpatrick et al. (1998) found that these injuries accounted for 34% of all fractures around the ankle (31). These may be more common in snowboarders because of the flexibility of the boot and loading mechanism (31), and are more common in the leading foot (66). These fractures may be difficult to assess on plain radiographs, and there is discrepancy which radiographic views are optimal to assess lateral process fractures (17). Occasionally, there is the presence of a V-sign on the lateral radiograph, which is pathognomonic for a displaced lateral process of the talus fracture (concentric V-shaped articulation of the talus with the subtalar joint is disrupted (69); (Fig. 5). If there is any clinical or radiographic suspicion for a lateral process fracture, a CT scan should be obtained.

Lateral process of the talus fractures are often misdiagnosed as an ankle sprain, and require a high index of suspicion to make the correct diagnosis. This is critical because lateral process of the talus fractures can have a much worse prognosis than ankle sprains if treated inappropriately. Some history and physical exam features which may heighten the suspicion for a lateral process fracture include a history of a "sprained ankle", point tenderness 1 cm distal to the lateral malleolus, and a history of snowboarding when the injury occurred (38). A lateral process stress test may also help establish the diagnosis (66). The leg is held in external rotation, and a dorsiflexion and eversion torque is applied to the foot while maintaining an axial load on the foot. This will load the articular facet and cause pain in lateral process of the talus fractures (66).

Loading the lateral process with the lateral process stress test provides clues towards the pathomechanics most frequently causing this fracture. These injuries were originally thought to be a result of dorsiflexion and inversion (38, 40). More recent biomechanical studies have reproducibly shown that fractures are a result of dorsiflexion and eversion (23) or external rotation (8). These biomechanical studies correlate with Valderabammo's study in which injured snowboarders were questioned regarding the mechanism of injury; injuries were from dorsiflexion and either external rotation, eversion, or a combination of these mechanisms (66).

Treatment

Treatment relies on an accurate diagnosis, which is key given the intraarticular nature of the lateral process. McCrory and Bladin (1996) presented a classification system to help guide treatment (38). Type 1 fractures are small chip fractures of the anteroinferior portion of the lateral process and may represent an avulsion of the anterior talofibular ligament. These fractures do not extend into the talofibular articulation. Type 2 fractures represent a single large fragment that extends from the talofibular articular surface to the posterior talocalcaneal articular surface (2A are nondisplaced and 2B are displaced). Type 3 fractures are comminuted and often involve the entire lateral process. Type 1 fractures and nondisplaced fractures can be treated non-operatively with non-weight bearing for 6 weeks. Given the articular nature of the lateral process, displaced fragments should be fixed with open reduction and internal fixation (large fragments), or excision (small fragments) (38, 66).

Outcomes

If diagnosed early and treated properly, patients with lateral process fractures can have high American Orthopaedic Foot and Ankle Society (AAFAOS) hindfoot scores and do well (66, 69). Operatively and non-operatively managed patients may have a small decrease in subtalar joint range of motion (66). If there is fracture displacement, operatively managed patients may do better and have a lower rate of revision surgery

(66). Non-operative management may lead to a symptomatic nonunion eventually requiring debridement (66, 49). Patients presenting late can have poor outcomes and often require secondary surgeries such as debridement and fragment excision (49). Associated local injuries are common and may influence outcomes. In a cohort study of 23 snowboarders with lateral process fractures, Von Knoch (2007) showed that there was an 88% incidence of concurrent injuries including calcaneal chondral lesions, ligament injuries (calcaneofibular ligament most common), and peroneal tendon subluxation (69). Subtalar arthritis was present in 45% of patients at 3.5 years follow-up, and was found in patients with delayed presentation, a comminuted fracture pattern, or those complicated by associated injuries (69). The long-term incidence of subtalar arthritis and outcome is unknown.

POSTERIOR PROCESS OF THE TALUS FRACTURES

Anatomy

The posterior process of the talus has a superior articulation with the tibia and an inferior articulation with the subtalar joint comprising 25% of the posterior facet (41). The posterior process is divided into medial and lateral (the lateral tubercle is larger and is eponymously termed Stieda's process) tubercles, and the sulcus between the tubercles contains the flexor hallucis longus tendon. Commonly, an os trigonum exists posterior to the lateral process. The Y-shaped bifurcate talocalcaneal ligament inserts onto each tubercle, and the posterior talofibular ligament commonly inserts on the lateral tubercle (47). The posterior portion of the deltoid ligament (posterior talotibial ligament) inserts on the medial tubercle.

Pathomechanics

Fractures of the posterior process are rare and can be from a ligamentous avulsion or direct loading. Dorsi-flexion and eversion can avulse the medial process via the posterior talotibial ligament (Cedell fracture) (13). Plantarflexion and inversion may cause a lateral process avulsion fracture (Shepherd's fracture) (58). Direct loading fractures often are caused by hyperplantar flexion compressing the posterior process between the posterior malleolus and calcaneus (47).

Presentation/Imaging

As with lateral process of the talus fractures, a high index of suspicion is required for diagnosis as these fractures are frequently missed (30, 43). In a retrospective study by Paulos et al. (1983), twenty patients were assessed and the average number of physician visits before being diagnosed with a posterior talar process fracture was 5.8 (47). Patients may have a suspicious description of mechanism (e.g. hyperplantarflexion), and be tender in the posterior aspect of the ankle joint. Posterior ankle pain may be exacerbated by plantarflexion and/or resisted motion of the great toe (47). Radiographically, three views of the ankle may miss the fracture (19,43), and a 30° external rotation view of the ankle may help with diagnosis. If there is any suspicion of displacement, a CT scan should be ordered and used to judge fracture location and displacement (25).

Treatment/Outcomes

Avulsion fractures of the posterior process are typically extraarticular and may achieve a good result with immobilization and limited weight bearing (30). Untreated avulsions do poorly; however, untreated fractures can achieve a comparably good long-term outcome if treated with late excision (30). If missed, posterior process fractures can be a cause for ongoing posterior ankle pain or tarsal tunnel syndrome (47, 61). Sometimes posterior process of the talus fractures are an indicator of a more serious injury, such as a subtalar dislocation (25). If this is the case, outcomes are much worse. Guiffida et al. (2003) presented a case series of 6 patients with posteromedial talar process fractures, and all were associated with medial subtalar dislocations (25). Of the six, four were misdiagnosed originally as having an os trigonum. Of these patients, 4 underwent eventual subtalar fusion, one underwent tibio-talar-calcaneal fusion, and one was recommended a subtalar fusion for ongoing symptoms but did not proceed with surgery. The authors stress that appropriate diagnosis is key to successful management, and hinges on a good history of pathomechanics, and physical examination, which can guide imaging.

EXTRUDED TALUS

Pathomechanics

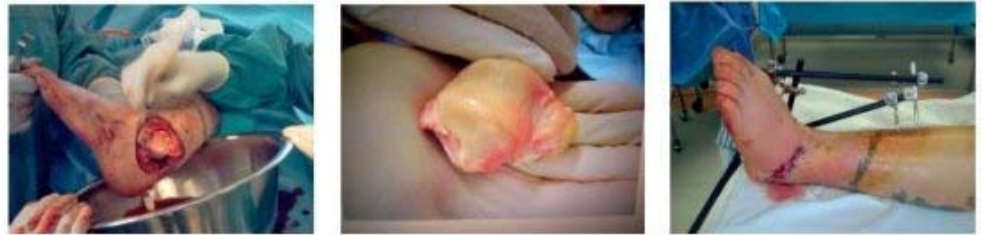Talar extrusions are possibly the most devastating talar injury, and are the result of large amounts of force being transmitted to the foot. Leitner (1955) postulated that total talar extrusions were the end result of the same vectors that cause subtalar dislocations; excessive supination or pronation forces cause the talus to dislocate laterally or medially, respectively (34). These injuries are high energy. In the largest retrospective case series of talar extrusions, Smith et al. (2006) found that motor vehicle collisions were the most common mechanism, and wounds can be lateral, medial, posteromedial, anterolateral, or anterior (59). As a result of the high energy and frequently open extrusion of the talus, there is often a complete stripping of the entire blood supply of the talus, which intuitively carries a poor prognosis (Fig. 6).

Treatment/Outcomes

Historically, outcomes have been poor due to high rates of infection (16, 36) and AVN (16, 28, 32, 57). As such, some initial treatment recommendations included talectomy and arthrodesis (16) or primary arthrodesis (32). Primary arthrodesis was advocated because of the theoretical difficulty in achieving fusion in osteonecrotic bone (48). This has not been borne out in the literature, as there are many successful

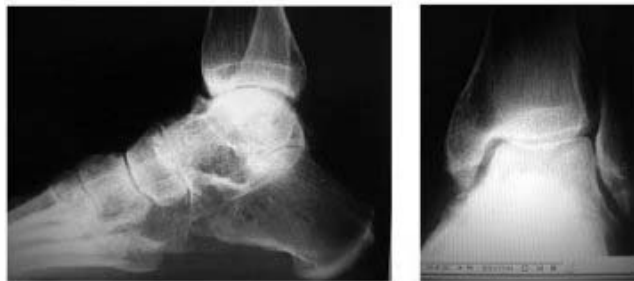reports of late arthrodeses in osteonecrotic tali (59, 67). More recent large retrospective case series have shown that the rate of AVN and infection may not be as high as previously thought. Smith et al. (2006) showed that none of the 19 patients with open extruded talus injuries had an infection related to reimplantation, and that on radiographic follow-up at one year, not all had poor outcomes (59). Of the eight patients with a talar body fracture, all had AVN, collapse, or arthritis, and of the 5 patients without a fracture, only one had arthritis and one had AVN without collapse (59). In a retrospective case series of 8 patients with talar extrusions, Burston et al (2010) showed that only two had infections (one K-wire infection and one joint infection), and only 5 had AVN (only one of the those with AVN went on to collapse; the patient with the deep infection) (11). In this same paper Burston et al. summarized the current literature on talar extrusion and found that the overall infection rate for extruded talus injuries was 20%, the overall AVN rate was 30% and the osteoarthritis rate was 16% (64) (Fig. 7).

Based on
the



a b c

Fig. 6. Extruded talus debridement before and after reimplantation.



a b

Fig. 7. Extruded talus and status 6 years postoperatively.

forementioned outcome data, the authors recommend reimplanting the talus whenever possible, with meticulous attention to cleaning the talus. The benefits of talar reimplantation are preservation of the normal hindfoot shape and mechanics and preservation of bone stock for future reconstructive procedures. Adjuncts required to maintain talar position following reduction include soft tissue imbrication or K-wires (if unstable with soft tissue repair alone) to hold the triple joint complex in anatomic position. Decisions should be made on an individual basis. The largest drawback of talar reimplantation is potential for infection (36). Infection may be the most important determinant of patient outcome (11). Smith et al. (2006) did not have infections relating to reimplantation and used a cleansing protocol where they placed the talus in a sterile Bacitracin solution, followed by gentle intraoperative scrubbing and two or three serial Bacitracin washes before reimplantation (59). In vitro studies show that other protocols such as gentle cleaning with 10% Povidone-iodine solution followed by a normal saline wash may have an optimal balance between microbial kill and chondrocyte preservation (10).

Subsequent to talus reimplantation and non-weight-bearing for approximately 8 weeks, patients should be treated expectantly. There is a possibility that the talus may become revascularized on long-term follow up (3). If AVN develops, continued weight bearing and activity as tolerated is acceptable (59). Salvage surgeries for symptomatic control include subtalar, tibiotalar, or tibiototalcalcaneal arthrodesis, talectomy with fibrous arthroplasty, tibio-calcaneal arthrodesis or, ankle arthroplasty with subtalar arthrodesis, or amputation. These decisions should be made on an individual basis.

Given how rare these injuries are, functional outcomes reported are limited to a small number of case reports. If patients avoid early infection, it is possible to have average to good function post injury (4, 9, 28, 45, 59). In the retrospective case series presented by Burston et al. (2010), 4 of 8 patients had equal range of motion compared to the contralateral uninjured side, and there is often little correlation with AVN and functional outcome (11). If there is a need for secondary surgeries, patients may often have continued disability. In Smith's retrospective case series, 7 of 19 required secondary surgeries and had continued disability (59). Overall, the functional outcome for talar extrusions is similar to talar body fractures (59, 68), and poor prognostic factors include an associated deep infection (11, 36).

CONCLUSIONS

Injuries to the talus have a wide spectrum of clinical presentation from low-energy ankle sprains (lateral and posterior process fractures), to high-energy open injuries with significant soft tissue disruption. Knowledge of the precise anatomy of the talus and its blood supply will help guide treatment and prognosis. Regardless of presentation, the treating physician must be vigilant to pathomechanics, associated injuries and treatment options. If lateral and posterior process injuries are appropriately diagnosed, patients may have good outcomes. If neglected, patients may require salvage surgeries such as a subtalar arthrodesis. Higher energy injuries (talar head, neck, and body fractures and talar extrusions) must be recognized and treated

appropriately to provide a possibility of a good outcome. In most instances, the treating surgeon should strive for anatomic open reduction and internal fixation. Talar neck and body fractures and talar extrusions may be complicated by AVN, even if treated appropriately. AVN may or may not influence outcome, and not all cases of AVN are associated with talar dome collapse. Patients with AVN can be managed in accordance with their clinical symptoms, and salvage procedures can be prescribed accordingly.

References

1. ADELAAR, R. S.: Complex fractures of the talus. Instr. Course Lect., 46: 323-338, 1997.
2. ANDERSON, H.: The Medical and Surgical Aspects of Aviation. London: Henry Frowde Oxford University Press, 1919.
3. APOSTLE, K. L., UMRAN, T., PENNER, M. J.: Reimplantation of a totally extruded talus: a case report. J. Bone Jt Surg., 92-A: 1661-1665, 2010.
4. ASS AL, M., STERN, R.: Total extrusion of the talus. A case report. J. Bone Jt Surg., 86-A: 2726-2731, 2004.
5. ASTION, D. J., DELAND, J. T., OTIS, J. C., KENNEALLY, S.: Motion of the hindfoot after simulated arthrodesis. J. Bone Jt Surg., 79-A: 241-246, 1997.
6. ATTIAH, M., SANDERS, D. W., VALDIVIA, G., COOPER, I., FERREIRA, L., MACLEOD, M. D., JOHNSON, J. A.: Comminuted talar neck fractures: a mechanical comparison of fixation techniques. J. Orthop. Trauma, 21: 47-51, 2007.
7. BELLAMY, J. L., KEELING, J. J., WENKE, J., HSU, J. R.: Does a longer delay in fixation of talus fractures cause osteonecrosis? J. Surg. Orthop. Adv., 20: 34-37, 2011.
8. BOON, A. J., SMITH, J., ZOBITZ, M. E., AMRAMI, K. M.: Snowboarder's talus fracture. Mechanism of injury. Am. J. Sports Med., 29: 333-338, 2001.
9. BREWSTER, NT., MAFFULLI, N.: Reimplantation of the totally extruded talus. J. Orthop. Trauma, 11: 42-45, 1997.
10. BRUCE, B., SHEIBANI-RAD, S., APPELYARD, D., CALFEE, R. P., REINERT, S. E., CHAPIN, K. C., DIGIOVANNI, C. W.: Are dropped osteoarticular bone fragments safely reimplantable in vivo? J. Bone Jt Surg., 93-A: 430-438, 2011.
11. BURSTON, J. L., ISENEGGER, P., ZELLWEGER, R.: Open total talus dislocation: clinical and functional outcomes: a case series. J. Ttrauma, 68: 1453-1458, 2010.
12. CANALE, S. T., KELLY, F. B.: Fractures of the neck of the talus. Long-term evaluation of seventy-one cases. J. Bone Jt Surg., 60-A: 143-156, 1978.
13. CEDELL, C. A.: Rupture of the posterior talotibial ligament with the avulsion of a bone fragment from the talus. Acta Orthop. Scand., 1974; 45-3: 454-61.
14. COLTART, W. D.: Aviators astragalus. J. Bone Jt Surg., 34-B: 545-566, 1952.
15. DANIELS, T. R., SMITH, J. W., ROSS, T. L.: Varus malalignment of the talar neck. Its effect on the position of the foot and on subtalar motion. J. Bone Jt Surg., 78-A: 1559-1567, 1996.
16. DETENBECK, L. C., KELLY, P. J.: Total dislocation of the talus. J. Bone Jt Surg., 51-A: 283-288, 1969.
17. DIMON, J. H., 3rd: Isolated displaced fracture of the posterior facet of the talus. J. Bone Jt Surg., 43-A: 275-281, 1961.
18. EBRAHEIM, N. A., MEKHAIL, A. O., SALPIETRO, B. J., MERMER, M. J., JACKSON, W. T.: Talar neck fractures: anatomic considerations for posterior screw application. Foot Ankle Int. 17: 541-547, 1996.
19. EBRAHEIM, N. A., MEKHAIL, A. O., YEASTING, R. A.: Components of the posterior calcaneal facet: anatomic and radiologic evaluation. Foot Ankle Int., 17: 751-757, 1996.
20. ELGAFY, H., EBRAHEIM, N. A., TILE, M., STEPHEN, D., KASE, J.: Fractures of the talus: experience of two level 1 trauma centers. Foot Ankle Int., 21: 1023-1029, 2000.
21. ESTRADA, L. S., ALONSO, J. E., MCGWIN, G., METZGER, J., RUE, L. W.: Restraint use and lower extremity fractures in frontal motor vehicle collisions. J. Ttrauma, 57: 323-328, 2004.
22. FRAWLEY, P. A., HART, J. A., YOUNG, D. A.: Treatment outcome of major fractures of the talus. Foot Ankle Int., 16: 339-345, 1995.
23. FUNK, J. R., SRINIVASAN, S. C. M., CRANDALL, J. R.: Snow-boarder's talus fractures experimentally produced by eversion and dorsiflexion. Amer. J. Sports Med., 31:921-928, 2003.
24. GELBERMAN, R. H., MORTENSEN, W. W.: The arterial anatomy of the talus. Foot Ankle, 4: 64-72, 1983.
25. GIUFFRIDA, A. Y., LIN, S. S., ABIDI, N., BERBERIAN, W., BERKMAN, A., BEHRENS, F. F.: Pseudo os trigonum sign: missed posteromedial talar facet fracture. Foot Ankle Int., 24: 642-649, 2003.
26. HANSEN, S.: Functional Reconstruction of the Foot and Ankle. Philadelphia: Lippincott Williams & WIMns, 2000.

27. HAWKINS, L. G.: Fractures of the neck of the talus. *J. Bone Jt Surg.*, 52-A: 991-1002, 1970.
28. HIRAZUMI, Y., HARA, T., TAKAHASHI, M., MAYEHIYO, S.: Open total dislocation of the talus with extrusion (missing talus): report of two cases. *Foot Ankle*, 13: 473-477, 1992.
29. INOKUCHI, S., OGAWA, K., UŠAMI, N.: Classification of fractures of the talus: clear differentiation between neck and body fractures. *Foot Ankle Int.*, 17: 748-750, 1996.
30. KIM, D. H., BERKOWITZ, M. J., PRESSMAN, D. N.: Avulsion fractures of the medial tubercle of the posterior process of the talus. *Foot Ankle Int.*, 24: 172-175, 2003.
31. KIRKPATRICK, D. P., HUNTER, R. E., JANES, P. C., MASTRANGELO, J., NICHOLAS, R. A.: The snowboarder's foot and ankle. *Am. J. Sports Med.*, 26: 271-277, 1998.
32. KRASIN, E., GOLDWIRTH, M., OTREMSKI, I.: Complete open dislocation of the talus. *J. Accid. Emerg. Med.*, 17: 53-54, 2000.
33. LEITNER, B.: Obstacles to reduction in subtalar dislocations. *J. Bone Jt Surg.*, 36-A: 2:299-306, 1954.
34. LEITNER, B.: The mechanism of total dislocation of the talus. *J. Bone Jt Surg.*, 37-A: 89-95, 1955.
35. LINDVALL, E., HAIDUKEWYCH, G., DIPASQUALE, T., HERSCOVICI, D., SANDERS, R.: Open reduction and stable fixation of isolated, displaced talar neck and body fractures. *J. Bone Jt Surg.*, 86-A: 2229-2234, 2004.
36. MARSH, J. L., SALTZMAN, C. L., IVERSON, M., SHAPIRO, D. S.: Major open injuries of the talus. *J. Orthop. Trauma*, 9: 371-376, 1995.
37. MATSUMURA, T., SEKIYA, H., HOSHINO, Y.: Correction osteotomy for malunion of the talar head: a case report. *J. Orthop. Surg.*, (Hong Kong) 16: 96-98, 2008.
38. McCRORY, P., BLADIN, C.: Fractures of the lateral process of the talus: a clinical review. "Snowboarder's ankle". *Clin. J. Sports Med.*, 6: 124-128, 1996.
39. MILLER, A. N., PRASARN, M. L., DYKE, J. P., HELFET, D. L., LORICH, D. G.: Quantitative assessment of the vascularity of the talus with gadolinium-enhanced magnetic resonance imaging. *J. Bone Jt Surg.*, 93-A: 1116-1121, 2011.
40. MUKHERJEE, S. K., PRINGLE, R. M., BAXTER, A. D.: Fracture of the lateral process of the talus. A report of thirteen cases. *J. Bone Jt Surgm*, 56-B: 263-273, 1974.
41. NADIM, Y., TOSIC, A., EBRAHEIM, N.: Open reduction and internal fixation of fracture of the posterior process of the talus: a case report and review of the literature. *Foot Ankle Int.*, 20: 50-52, 1999.
42. NICHOLAS, R., HADLEY, J., PAUL, C., JAMES, P.: "Snowboarder's fracture": fracture of the lateral process of the talus. *J. Am. Board Fam. Pract.*, 7: 130-133, 1994.
43. NYSKA, M., HOWARD, C. B., MATAN, Y., COHEN, D., PEYSER, A., GARTI, A., BAR-ZIV, J.: Fracture of the posterior body of the talus?the hidden fracture. *Arch. Orthop. Trauma Surg.*, 117: 114-117, 1998.
44. OHL, X., HARISBOURE, A., HEMERY, X., DEHOUX, E.: Long-term follow-up after surgical treatment of talar fractures: Twenty cases with an average follow-up of 7.5 years. *Int. Orthop.*, 35: 93-99, 2011.
45. PALOMO-TRAVER, J. M., CRUZ-RENOVELL, E., GRANELL-BELTRAN, V., MONZONIS-GARCIA, J.: Open total talus dislocation: case report and review of the literature. *J. Orthop. Trauma*, 11:45-49, 1997.
46. PATEL, R., VAN BERGEYK, A., PINNEY, S.: Are displaced talar neck fractures surgical emergencies? A survey of orthopaedic trauma experts. *Foot Ankle Int.*, 26: 378-381, 2005.
47. PAULOS, L. E., JOHNSON, C. L., NOYES, F. R.: Posterior compartment fractures of the ankle. A commonly missed athletic injury. *Am. J. Sports Med.*, 11: 439-443, 1983.
48. PENNY, J. N., DAVIS, L. A.: Fractures and fracture-dislocations of the neck of the talus. *J. Trauma*, 20: 1029-1037, 1980.
49. PERERA, A., BAKER, J. F., LUI, D. F., STEPHENS, M. M.: The management and outcome of lateral process fracture of the talus. *Foot Ankle Surg.*, 16: 15-20, 2010.
50. PETERSON, L., ROMANUS, B., DAHLBERG, E.: Fracture of the collum tali?an experimental study. *J. Biomech.*, 9: 277-279, 1976.
51. PRASARN, M. L., MILLER, A. N., DYKE, J. P., HELFET, D. L., LORICH, D. G.: Arterial anatomy of the talus: a cadaver and gadolinium-enhanced MRI study. *Foot Ankle Int.*, 31: 987-993, 2010.
52. RAMMELT, S., ZWIPP, H.: Talar neck and body fractures. *Injury*, 40: 120-135, 2009.
53. ROSS, P. M., MITCHELL, D. C.: Dislocation of the talonavicular joint: case report. *J. Trauma*, 16: 397-401, 1976.
54. ROSSI, F., DRAGONI, S.: Talar body fatigue stress fractures: three cases observed in elite female gymnasts. *Skeletal Radiol.*, 34: 389-394, 2005.
55. SANDERS, D. W., BUSAM, M., HATTWICK, E., EDWARDS, J. R., MCANDREW, M. P., JOHNSON, K. D.: Functional outcomes following displaced talar neck fractures. *J. Orthop. Trauma*, 18: 265-270, 2004.

56. SANGEORZAN, B. J., WAGNER, U. A., HARRINGTON, R. M., TENCER, A. F.: Contact characteristics of the subtalar joint: the effect of talar neck misalignment. J. Orthop. Res., 10: 544-551, 1992.
57. SCHIFFER, G., JUBEL, A., ELSNER, A., ANDERMAHR, J.: Complete talar dislocation without late osteonecrosis: clinical case and anatomic study. J. Foot Ankle Surg., 46:120-123, 2007.
58. SHEPHERD, F.: A Hitherto Undescribed Fracture of the Astralgus. J. Anat. Physiol., 17: 79-81, 1883.
59. SMITH, C. S., NORK, S. E., SANGEORZAN, B. J.: The extruded talus: results of reimplantation. J. Bone Jt Surg., 88-A: 2418-2424, 2006.
60. SNEPPEN, O., CHRISTENSEN, S. B., KROGSOE, O., LORENTZEN, J.: Fracture of the body of the talus. Acta Orthop. Scand., 48: 317-324, 1977.
61. STEFKO, R. M., LAUERMAN, W. C., HECKMAN, J. D.: Tarsal tunnel syndrome caused by an unrecognized fracture of the posterior process of the talus (Cedell fracture). A case report. J. Bone Jt Surg., 76-A: 116-118, 1994.
62. SWANSON, T. V., BRAY, T. J., HOLMES, G. B., Jr.: Fractures of the talar neck. A mechanical study of fixation. J. Bone Jt Surg., 74-A: 544-551, 1992.
63. SYME, J.: Contribution to the pathology and practice of surgery. Edinburgh: Sutherland & Knox, 1848.
64. TANG, H., HAN, K., LI, M., ZHANG, Q., XIE, Y., TANG, X., XU, H., MAO, N.: Treatment of Hawkins type II fractures of talar neck by a vascularized cuboid pedicle bone graft and combined internal and external fixation: a preliminary report on nine cases. J. Trauma, 69: E1-5, 2010.
65. TEZVAL, M., DUMONT, C., STURMER, K. M.: Prognostic reliability of the Hawkins sign in fractures of the talus. J. Orthop. Trauma, 21:538-543, 2007.
66. VALDERRABANO, V., PERREN, T., RYF, C., RILLMANN, P., HINTERMANN, B.: Snowboarder's talus fracture: treatment outcome of 20 cases after 3.5 years. AAm. J. Sports Med., 33: 871-880, 2005.
67. VALLIER, H. A., NORK, S. E., BAREI, D. P., BENIRSCHKE, S. K., SANGEORZAN, B. J.: Talar neck fractures: results and outcomes. J. Bone Jt Surg., 86-A: 1616-1624, 2004.
68. VALLIER, H. A., NORK, S. E., BENIRSCHKE, S. K., SANGEORZAN, B. J.: Surgical treatment of talar body fractures. J. Bone Jt Surg., 85-A: 1716-1724, 2003.
69. VON KNOCH, F., RECKORD, U., VON KNOCH, M., SOMMER, C.: Fracture of the lateral process of the talus in snowboarders. J. Bone Jt Surg., 89-B: 772-777, 2007.

Zpět

PRÁVĚ VYCHÁZÍ:



