




Available online at
 ScienceDirect
www.sciencedirect.com

Elsevier Masson France

www.em-consulte.com/en



TECHNICAL NOTE

Reversed anatomic distal femur locking plate for periprosthetic hip fracture fixation

M. Ehlinger^{a,*}, D. Brinkert^a, J. Besse^a, P. Adam^a, Y. Arlettaz^b, F. Bonnomet^a

^a Orthopaedic and Traumatologic Surgery Dept, Hautepierre Hospital, Strasbourg University Hospitals, 1, avenue Molière, 67098 Strasbourg cedex, France

^b Orthopedic and Traumatologic Surgery Dept, Hôpital du Valais, 80, avenue Grand-Champsec, 1951 Sion, Switzerland

Accepted: 13 December 2010

KEYWORDS

Femoral fracture;
Locking plate;
Femoral fracture on
previous implants

Summary The incidence of femoral fracture on hip prosthesis is increasing. Plate fixation is the method of choice when the prosthesis is stable. In fracture with proximal extension, the quality of the bone fixation is critical and, despite the development of anatomic plates, may be endangered when there are too few proximal screws. To resolve this issue, we recommend using a reversed LCPTM anatomic distal femoral Less Invasive Stabilization System (LISSTM) locking plate: e.g., a left distal femoral plate for femoral fracture on right-hip implant. This presents several advantages: minimally invasive surgery, the introduction of the plate being facilitated by the LISSTM ancillary; ease of locking, also thanks to the ancillary; and, above all, multiple proximal trochanteric fixation thanks to the form of this anatomic distal LISSTM plate, improving proximal bone fixation. The present technical note seeks to illustrate the interest of using a “reversed” plate, in terms of simplicity of fitting and quality of reduction and consolidation, while also specifying the associated limitations and tolerance.

© 2011 Elsevier Masson SAS. All rights reserved.

Introduction

Femoral fracture on hip implant is relatively rare, at 0.1–2% [1], but is becoming increasingly frequent as the number of hip replacements increases and the population ages. Osteosynthesis techniques in these indications are a subject of debate, but plates are used in almost 85% of cases [1].

Although anatomic plates have been developed, proximal trochanteric fixation is not always straightforward, especially when the fracture line extends proximally. Proximal fixation is important in these cases, to limit the impact of varizing forces which could loosen the material. We therefore recommend using the LCPTM anatomic distal femoral Less Invasive Stabilization System (LISSTM) locking compression plate (SynthesTM, Solothurn, Switzerland) in a reversed situation: e.g., right plate for left hip. The aim is to enhance trochanteric fixation by increasing the number of proximal screws while enabling the LISSTM ancillary to be introduced by a minimal approach.

The present note details this original osteosynthesis technique.

* Corresponding author. Tel.: +33 3 88 12 77 19;

fax: +33 3 88 12 77 13.

E-mail address: matthieu.ehlinger@chru-strasbourg.fr (M. Ehlinger).

Indications and objectives

Ideally, the fracture should be type B1 on the Vancouver classification [2]. Certain B2 fractures may be indications if free of preoperative pain or in elderly patients for whom this attitude is one of salvage with minimal surgical aggression. With anatomic diaphyseal plates, the presence of the metaphyseal implant may prevent the use of bicortical locking screws in the proximal fragment, due to their monoaxial nature. In contrast, the plate recommended here enables fixation in the proximal metaphysis behind and forward of the implant thanks to the width of the splayed part of the plate and the number of screws that can be used, whether uniaxial locking screws or especially standard screws the direction of which can be adjusted (Fig. 1).

Surgical technique

We use large-fragment locking screws in titanium alloy (LCPTM, SynthesTM, Solothurn, Switzerland). The plate is fitted in a "reverse" position as we use the "anatomic distal femoral LISSTM plate". This is positioned using the LISSTM ancillary, which allows extraperiosteal introduction and manipulation, and above all, facilitates locked screwing (Fig. 1). Screws may be standard, screwing the bone back against the plate, or locked with classic locking screws or blunt screws for unicortical periprosthetic locking in case of implant obstruction. Bolts that can be screwed onto the plate are also available, to fix wires to the plate. This enables fixation independently of the friction between bone and plate classically required with plates using nonlocking screws.

Surgery is performed either in supine position on a traction table or in lateral decubitus (on the contralateral side) on a standard table. Traction table installation is as for anterograde intramedullary nailing, with traction by fracture-table boot or transosseous condylar K-wire. The thorax should be held back by a counter-support so as to give access to the trochanteric region. On a standard table, installation is as for hip replacement. Surgery should be performed under peroperative radioscopia. Traction table installation facilitates minimally invasive surgery, enabling AP and lateral radioscopic control with, if possible, two image intensifiers. In lateral decubitus, radioscopia will basically be on AP view, with the rod coming from the ceiling toward the ground, perpendicular to the femur, as a lateral view can only be taken at end of surgery by both gently rotating the hip and adjusting the X-ray equipment. Installation in lateral decubitus allows both a classic and a minimally invasive approach, although reduction is more difficult on the latter and requires greater peroperative X-ray control.

Whichever the type of installation, surgery begins with a short proximal paratrochanteric approach after locating and marking the various levels (implant, fracture limits, femoral axis) so as to minimize the duration of X-ray exposure [3]. Reduction is systematically attempted indirectly, using external maneuvers under X-ray control. If this does not succeed, various techniques may be employed [3]: temporary intrafocal K-wire, or lag screw. If this is still insufficient, the approach can be extended or converted (to a lateral

approach, raising the vastus lateralis), enabling reduction using bone-holding forceps or release of interposed muscle or cement. Whichever the type of installation, reduction and stabilization may be achieved by primary percutaneous cerclage, which facilitates subsequent introduction and positioning of the plate.

The plate is selected so as to have at least five screw-holes beyond the fracture line; the most frequently used have 11 or 13 holes (Fig. 1). It is "reversed": for a right proximal fracture, a left distal femoral anatomic plate is used. It is mounted on the LISSTM ancillary to facilitate introduction and manipulation (Fig. 1). The splayed part of the plate, which we call the "racket", is positioned as support, facing the shoulder of the greater trochanter (Fig. 2).

Once the plate is correctly positioned, fixation is direct, using locking screws, or else standard screws if the metaphyseal implant has to be avoided, as their orientation can be adapted so as to optimize fixation. Lateral positioning should first be checked on X-ray. With a conventional approach, the plate can then be temporarily stabilized by forceps. With a minimally invasive approach, soft-tissue conservation improves stabilization of the plate, which is held between the muscle and the bone. If plate application is not satisfactory, there are three possible solutions: (1) to extend the approach so as to introduce bone-holding forceps to grip the plate against the bone; (2) to use standard proximal screws to tighten the positioning; or (3) to fit lag cerclage. The "racket" allows a large number of screws to be used, so as to optimize proximal fixation. The rest of the assembly is classical, as previously described [3], following a strict charge-book to enable immediate postoperative partial weight-bearing up to the pain threshold [3]. We recommend a long assembly, with at least five screw-holes beyond the fracture. Alternating locking screws (one hole with screw and one without) optimizes the distribution and absorption of stress. If possible, three locking screws should be fitted per fragment: this is the advantage of reversed plates for high fracture, where the proximal fragment has limited bone capital. All screws fitted beyond the implant are bicortical. Screws at the level of the femoral shaft should also, if possible, be bicortical, but this has to be adapted to the presence of the implant and its position in flexion-extension: blunt unicortical screws are often needed, and should be as numerous as possible. Proximal screws should be as numerous as possible, with cement anchoring if necessary to improve fixation. If assembly fixation still seems unsure, stability should be enhanced by one or more lag cerclages, possibly fixed on a bolt screwed to the plate so as to avoid plate disassembly on weight-bearing. Finally, the locking screw fixation under the implant should be adapted to the type of fracture: close to the fracture site in complex fracture and more remote in simple fracture [4]. This variation compensates for the elasticity of titanium, by solidifying the assembly in complex fracture and leaving it "dynamic" in more simple cases.

Results

The technique was used in seven fractures in six patients: mean age, 83 years (range, 72–95 yrs); four women, two men, with cemented hip implants. Fractures were secondary

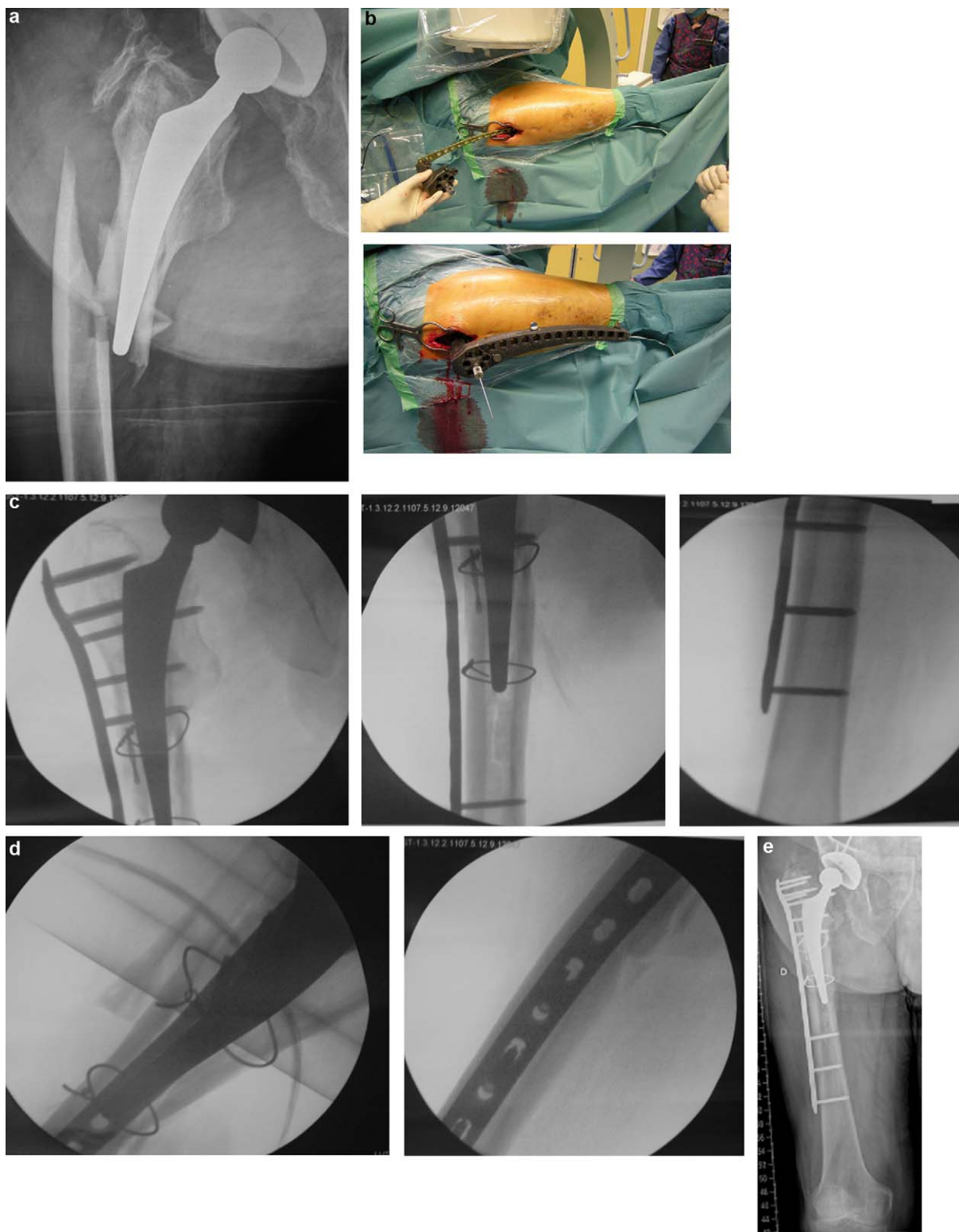


Figure 1 Application in type B1 fracture (Vancouver classification). (a) Preoperative AP X-ray, type B1 fracture. (b) Operative view of minimally invasive proximal approach. Use of LISS™ ancillary to facilitate plate introduction and locked screwing. Proximal K-wire enables control of plate level. (c) Final peroperative AP views. The "racket" of the distal femoral plate enables multiple (five locking screws) proximal fixation to the greater trochanter; the next three, more distal, screws are bicortical, to reinforce osteosynthesis. The screws introduced under the femoral shaft are spaced out to distribute and absorb stress. Traction and plate introduction were insufficient to obtain satisfactory reduction, and cerclage had to be performed on a limited approach to complete reduction before implanting the plate. (d) Final peroperative lateral views showing reduction and good alignment, particularly of the proximal "racket". (e) X-ray at 3 months' FU. Fracture consolidated; axis conserved; no secondary displacement.

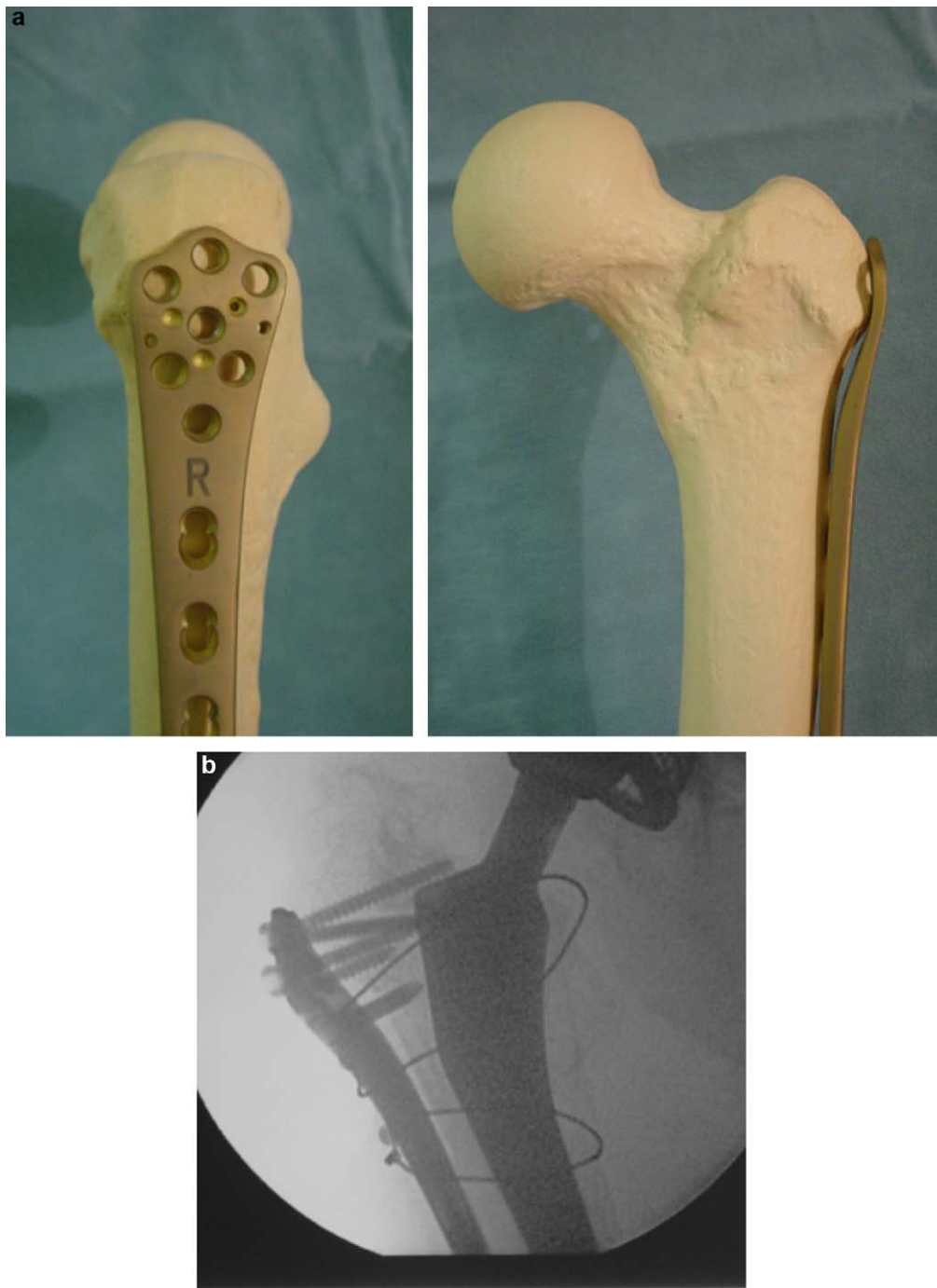


Figure 2 Positioning the plate on the proximal femur facing the greater trochanter's offset. The plate is positioned in support of the greater trochanter, a position that may cause discomfort in lateral decubitus. (a) Frontal and lateral positioning on dry bone: reversed right distal femur plate on left proximal femur. (b) Intraoperative view of reversed left plate on right proximal femur. Note standard screw, enabling directional proximal fixation and good support application of plate at the greater trochanter's offset.

to home accidents: four type B1, three type B2. The fractures extended to a mean 10 cm from the summit of the greater trochanter. 13-hole plates were used in five cases and 11-hole plates in two. Surgery was performed on a standard table in three cases and on a traction table in four. The approach was conventional in one case and minimally invasive in six. Axes were conserved. No complications

were observed. The presence of the plate on the greater trochanter caused no significant discomfort. Weight-bearing was authorized up to the pain threshold in three cases, partially in two and not at all in two others (one bilateral fracture with 10 weeks' nonweight-bearing, and one patient with an ipsilateral open fracture of the tibia, treated by nailing).

Discussion

The LCP™ plate, with screws “locked to the plate”, theoretically provides improved fixation in osteoporotic bone [5–7], which is an advantage in the population exposed to periprosthetic fracture. If implant obstruction allows, we recommend bicortical locking screws, which improve bone fixation and allow assembly with the LCP™ plate as an “internal fixator” [5–7]. The association of long assembly, to improve stress distribution and absorption, and fragment fixation using at least three or four screws (with associated cerclages as needed) enables, in our experience, immediate resumption of weight-bearing.

The “reversed” use of the plate was intended to achieve multiple proximal trochanteric fixation despite the metaphyseal presence of the implant. Such an assembly is of particular interest in fractures extending high up the proximal fragment, but is also useful for lower fractures when the implant constitutes a significant obstruction. To our knowledge, no classical devices enable such osteosynthesis; another publication reported similar success in a series of 13 femoral fractures with stable hip implants [8].

The equipment has the further advantage of including a LISS™ ancillary which facilitates plate positioning and allows minimally invasive distal screwing, even in conventional surgery, thereby limiting the approach below the fracture.

The method involves several limitations: principally, the proximal application of the plate, but also the sagittal curve of the plate, designed for the slightly more incurved distal femur. Special attention should be paid to lateral positioning. The difference in curvature can, on the other hand, be useful, facilitating the positioning of the screws around the femoral stem in the femoral shaft.

Conclusion

Fitting this reversed plate involves no particular difficulty on condition that two features are met: fixation on reduced

fracture, and verification of height and lateral positioning. Proximal fixation should be multiple. The ideal indication is for fracture extending high up the proximal femur. To facilitate use in minimally invasive surgery and application to the proximal femur, a dedicated proximal anatomic plate should be developed.

Disclosure of interest

ME, PA: occasional involvement as consultant for Synthes™; DB, JB, YA, FB: none.

References

- [1] Bégué T, Thomazeau H, Adam P, et al. Fractures périprothétiques autour des prothèses du genou et de la hanche. *Rev Chir Orthop* 2006;Suppl. 92:529–96.
- [2] Duncan CP, Masri BA. Fractures of the femur after hip replacement. *Instr Course Lect* 1995;44:293–304.
- [3] Ehlinger M, Bonnomet F, Adam P. Periprosthetic femoral fractures: the minimally invasive fixation option. *Orthop Trauma Surg Res* 2010;96:304–9.
- [4] Stoffel K, Dieter U, Stachowiak G, Gächter A, Kuster MS. How can stability in locked internal fixators be controlled? *Injury* 2003;34(Suppl. 2):11–9.
- [5] Perren SM. Evolution of the fixation of long bones fractures. The scientific basis of biological internal fixation: choosing a new balance between stability and biology. *J Bone Joint Surg (Br)* 2002;84:1093–110.
- [6] Luo CF. Locking compressive plating: a new solution for fractures in rheumatoid patients. *Mod Rheumatol* 2005;15:169–72.
- [7] Wagner M. General principles for the clinical use of the LCP. *Injury* 2003;34(Suppl. 2):31–42.
- [8] Ebraheim NA, Gomez C, Ramineni SK, Liu J. Fixation of periprosthetic femoral shaft fractures adjacent to a well-fixed femoral stem with reversed distal femoral locking plate. *J Trauma* 2009;66:1152–7.